



Original Article

Prognostic value of chest computed tomography in adult inpatients with coronavirus disease 2019 pneumonia in Goma, in the Democratic Republic of the Congo

Didier Ndyabo Ndabahweje¹, Olivier Mukuku², Charles Kangitsi Kahindo³, Michel Lelo Tshikwela⁴, Gertrude Luyeye Mvila⁴, Antoine Molua Aundu⁴, Jean Tshibola Mukaya⁴, Stanislas Okitotsho Wembonyama⁵, Zacharie Kibendelwa Tsongo⁶

¹Department of Medical Imagery, University of Goma, Goma, ²Department of Maternal and Child Health, Institut Supérieur des Techniques Médicales de Lubumbashi, Lubumbashi, ³Department of Internal Medicine, University of Goma, Goma, ⁴Department of Medical Imagery, University of Kinshasa, Kinshasa, ⁵Department of Pediatrics, University of Lubumbashi, Lubumbashi, ⁶Department of Internal Medicine, University of Kisangani, Kisangani, Democratic Republic of the Congo.

*Corresponding author:

Olivier Mukuku,
Department of Maternal and Child Health, Institut Supérieur des Techniques Médicales de Lubumbashi, Lubumbashi, Democratic Republic of the Congo.

oliviermukuku@yahoo.fr

Received: 20 December 2023
Accepted: 08 March 2024
EPub Ahead of Print: 16 April 2024
Published:

DOI
10.25259/JPATS_31_2023

Quick Response Code:



ABSTRACT

Objectives: Chest computed tomography (CT) plays a crucial role in evaluating patients with coronavirus disease 2019 (COVID-19) pneumonia. This study aimed to assess the association between initial chest CT findings and mortality in adult inpatients with COVID-19 in the city of Goma, North Kivu province, the Democratic Republic of the Congo.

Materials and Methods: This was a multicenter retrospective study of patients hospitalized in Goma with COVID-19 pneumonia who underwent chest CT from January 1, 2021, to December 31, 2022. For each patient included, two experienced radiologists independently reviewed the initial chest CT. A multivariate logistic regression was performed to identify chest CT findings associated with mortality at the 5% significance level.

Results: Of 76 patients included in the study, 26 (34.2%) died. The degree of lung parenchymal involvement >25% (adjusted odds ratio [aOR] = 16.27 [3.30–80.16]) and the presence of consolidations (aOR = 3.33 [1.00–11.47]) were predictive of mortality with an area under the receiver operating characteristic curve of 0.8392. Sensitivity was 73.08%, specificity was 82%, positive predictive value was 67.86%, and negative predictive value was 85.42%.

Conclusion: Lung involvement >25% and consolidations on chest CT appear to predict death in adult inpatients with COVID-19 pneumonia.

Keywords: Coronavirus disease 2019, Mortality, Chest computed tomography, Predictive factors

INTRODUCTION

The Coronavirus Disease 2019 (COVID-19) pandemic has resulted in an unprecedented global health crisis, with millions of cases and deaths reported worldwide. The management of patients with COVID-19 is complex and requires a thorough assessment of disease severity for informed clinical decision-making. Determination of viral RNA by reverse transcription polymerase chain reaction, which was the gold standard diagnostic technique until recently, has good specificity but controversial sensitivity (37–71% depending on the studies) and was sometimes inaccessible in certain hospitals during the very first wave of this pandemic. Therefore, work was undertaken to prove the value of chest computed tomography (CT) for diagnostic purposes.^[1] Chest CT

has become an essential diagnostic tool in the evaluation of patients with COVID-19 because of its high sensitivity for detecting COVID-19 infection-associated lung abnormalities, which are often quite characteristic of COVID-19 lesions.^[2,3] Certain chest CT images have been shown to be characteristic of COVID-19, such as the initial appearance of ground-glass opacities, followed by crazy paving images, and finally, consolidations. Lesions are usually bilateral, peripheral, posterior, and inferior.^[4,5] If the diagnosis of COVID-19 pneumonia is suspected without biological evidence, chest CT offers excellent diagnostic performance, with a sensitivity of 90% (95% confidence interval [CI]: 89–91%) and a specificity of 91% (95% CI: 91–92%).^[6] Several studies have shown that initial chest CT findings can provide valuable information about disease severity and prognosis in patients with COVID-19.^[7-9] Radiological features such as the extent of lung opacities, the presence of pleural effusion, consolidation, and nodules, and the involvement of the lung lobes have been associated with disease severity and an increased risk of complications and even death.^[8]

In addition, recent studies have suggested that chest CT findings could also be used as a predictor of mortality in patients with COVID-19. A study by Li *et al.*^[10] showed that the extent of lung opacities detected by chest CT was significantly associated with an increased risk of death in patients hospitalized with COVID-19. Similarly, a systematic review by Majrashi *et al.*^[11] found that the CT severity score can serve as a reliable prognostic indicator of the severity of COVID-19.

However, despite these promising results, there is still uncertainty as to the predictive value of initial chest CT findings for mortality in adult inpatients with COVID-19. As the clinical course of the disease is highly variable, it appeared essential to identify early on the chest CT findings predictive of poor outcomes. Furthermore, the potential prognostic value of chest CT during COVID-19 pneumonia has not yet been specifically examined in the Congolese population.

In the present study, we aim to evaluate the association between initial chest CT findings and mortality in adult inpatients with COVID-19 in Goma City, in North Kivu province in the Democratic Republic of the Congo (DRC).

MATERIALS AND METHODS

Type, period, and population of the study

This study was a retrospective, multicenter, and cross-sectional study conducted from January 1, 2021, to December 31, 2022. Three health facilities took part in the study in Goma City, in the province of North Kivu (in the DRC): The Clinique Internationale de Médecine avancée (CIMAK), the Hôpital Charité Maternelle and the Heal Africa Hospital.

The CIMAK is the only hospital in the city with a CT scan machine.

Patients included in this study had the following inclusion criteria: Aged ≥ 18 years; case of COVID-19 confirmed by reverse transcription-polymerase chain reaction, or suspected pulmonary embolism complicating COVID-19, or case of COVID-19 diagnosed based on clinical presentation (cough, respiratory distress, and fever), and chest CT images consistent with COVID-19. Patients under 18 years of age treated for COVID-19 or those with incomplete medical records were excluded from the study.

Radiological data were extracted from CT scan reports. Data were obtained from the medical records and administrative databases of the participating hospitals. The variables extracted from these databases were age, sex, clinical symptoms and signs, presence of other pre-existing medical conditions (including diabetes mellitus, hypertension, cancer, etc.), chest CT findings, and mortality during hospitalization.

Chest CT image acquisition technique

When pulmonary embolism was not suspected, chest CT scans were performed without intravenous contrast injection, with the patient supine and at the end of inspiration. If pulmonary embolism was suspected, chest CT scans were performed with intravenous contrast injection and bolus monitoring, with the patient positioned supine and breathing neutrally.

The various chest CT examinations were performed using a Siemens Somatom Scope 16-slice CT scanner. The low-dose protocol was used. Each examination was performed at 120 kV and between 100 mAs and 150 mAs. Collimation was 0.6 mm. The sections were each 2.5 mm thick, followed by reconstruction with a collimation of 1.25 mm. The topo scan delimited the field of examination from the apex to below the costophrenic sinuses, including the laterothoracic soft tissues.

In accordance with the World Health Organization protocol, patients and technicians wore masks and personal protective equipment, and complete decontamination was carried out after each examination.

Analysis of chest CT images

The visual scale recommended by the Société Française de Radiologie and the European Society of Radiology was used.^[12,13] It has the advantage of being simple, rapid, and effective. This method of quantification is an assessment of the entire lung parenchyma based on the following approximations: The right and left lower lobes each represents 25% of the total lung parenchyma, and the right and left upper lobes and the middle lobe each

represent 15% of the parenchyma. This method defines the following categories: Minimal (<10%), moderate (10–25%), extensive (26–50%), severe (51–75%), and critical (>75%). When the operator hesitates between two categories, it is recommended that the lower category should be preferred. For each patient included, the initial chest CT scan was reviewed retrospectively, blinded to the clinical course, and independently by two experienced radiologists (more than ten years in practice). The location, type, and extent of abnormalities on the chest CT scan were carefully observed and recorded. In the event of conflicting results, a consensus was reached during a further concurrent reading session by the two radiologists. The descriptive elements were graded on a standardized form, adapted from the scan report, and drawn up based on the recommendations of the Société Française de Radiologie, using the visual scale.^[12]

Statistical analysis

Qualitative variables were presented in the form of absolute frequencies and percentages, and quantitative variables were presented with the mean and standard deviation. The median and percentiles of the observed distribution were also calculated. Bivariate analyses were performed using the Pearson test at a 5% significance level. Adjusted odds ratios (aOR) with 95% CIs were calculated using a logistic regression model by the block entry method. The accuracy of the model was assessed using a receiver operating characteristic curve and by calculating the area under the curve (AUC). The independent variable was the patient's outcome during hospitalization, which was marked by either death or survival. All analyses were performed using STATA version 16 software.

Ethical considerations

This study was approved by the Medical Ethics Committee of the University of Goma (approval no. UNIGOM/CEM/009/2023). Confidentiality was ensured during data analysis.

RESULTS

During the study period, 745 patients were admitted to the three hospitals with COVID-19 symptoms. Of these, 669 patients were excluded from our retrospective analysis because a chest CT scan had not been performed at the time of admission or the medical record was incomplete. Consequently, 76 patients were included in the present analysis. With regard to the CT scan protocol, in eight of the 76 patients (12.6%), an additional series of slices after administration of the intravenous contrast injection was performed.

Of the 76 patients included, 26 (34.2%) died. [Table 1] shows the demographic and clinical characteristics of the

76 patients included, according to their clinical course during the hospitalization. The mean age was 56.1 ± 13.5 years; this mean was 60.2 ± 12.2 years for non-survivors and 53.9 ± 13.8 years for survivors. Comparison of these two means shows a statistically significant difference ($P = 0.0461$). 67.1% of the patients were male; this proportion was 76.9% for the non-survivor patients and 62% for the survivors; we noted no statistical difference between these two proportions ($P = 0.2908$). We noted that 11.6% of non-survivors had ischemic heart disease, while none of the survivors did; a comparison between these two groups shows a statistically significant difference ($P = 0.0369$).

There was no statistical difference between the two groups in the proportions of diabetes mellitus and hypertension. With regard to clinical signs, no statistical correlation was observed between mortality and the following signs: Cough, fever, fatigue, myalgia, and gastrointestinal symptoms ($P > 0.05$). On the other hand, we noted that the mean respiratory rates of these two groups were statistically different (28.6 ± 8.2 breaths per minute for non-survivors and 23.1 ± 5.1 breaths per minute for the survivors; $P = 0.0006$). Similarly, for resting oxygen saturation levels, non-survivors had a mean of $71.9 \pm 24.1\%$ compared with $88.9 \pm 9.5\%$ for survivors ($P = 0.0016$).

Table 2 shows the correlations in bivariate analysis between the chest CT findings and the clinical outcomes of the patients. We observed significantly higher proportions of right middle lobe, right upper lobe, and left upper lobe involvements, as well as images of consolidation, crazy-paving, and pleural effusion in non-survivors compared with survivors ($P < 0.05$). We also noted that 96.1% of non-survivors had all five lobes affected compared with 70% of survivors ($P = 0.0076$). As for the degree of lung parenchymal involvement, 80.8% of non-survivors had severe/critical involvement (>50%) compared with 12% of survivors ($P < 0.0001$).

The results of the multivariate logistic regression are shown in Figure 1. The degree of lung parenchymal involvement and consolidations were identified as independent factors affecting clinical course. Patients with >25% lung involvement were more than 16 times more likely to die from COVID-19 than those with $\leq 25\%$ lung involvement (aOR = 16.27 [3.30–80.16]; $P < 0.0001$). Patients with consolidations were 3.33 times more likely to die from COVID-19 than those without (aOR = 3.33 [1.00–11.47]; $P = 0.0478$) [Figure 1].

The prediction of mortality by the degree of lung involvement >25% and the presence of consolidations on chest CT in adult inpatients with COVID-19 had a sensitivity of 73.08%, a specificity of 82%, a positive predictive value of 67.86%, and a negative predictive value of 85.42%. The AUC was 0.8392 [Figure 2].

Table 1: Demographic and clinical characteristics and comorbidities of the 76 patients on admission in relation to clinical course.

Variable	Total (n=76)	Non-survivors (n=26)	Survivors (n=50)	P-value
Age (years)				
Mean (\pm SD)	56.1 (\pm 13.5)	60.2 (\pm 12.2)	53.9 (\pm 13.8)	0.0461
Median (IQR)	55.5 (46.5–66.0)	60.5 (51–66)	53.0 (42–66)	
Min – Max	23–94	37–94	23–80	
Sex, n (%)				
Male	51 (67.1)	20 (76.9)	31 (62.0)	0.2908
Female	25 (32.9)	6 (23.1)	19 (38.0)	
Comorbidity, n (%)				
Hypertension	33 (43.4)	14 (53.9)	19 (38.0)	0.2808
Diabetes mellitus	19 (25.0)	9 (34.6)	10 (20.0)	0.2641
Ischemic heart disease	3 (3.9)	3 (11.5)	0 (0.0)	0.0369
Cough	53 (69.7)	16 (61.5)	37 (74.0)	0.3905
Dyspnea	49 (64.5)	22 (84.6)	27 (54.0)	0.011
Myalgia	10 (13.2)	5 (19.2)	5 (10.0)	0.4403
Fatigue	48 (63.2)	19 (73.1)	29 (58.0)	0.2974
Fever (temperature \geq 37.5°C)	23 (30.3)	7 (26.9)	16 (32.0)	0.8462
Gastrointestinal symptoms	11 (14.5)	1 (3.9)	10 (20.0)	0.0857
Temperature (°C)				
Mean (\pm SD)	37.1 (\pm 1.0)	36.9 (\pm 1.1)	37.2 (\pm 1.0)	0.8029
Median (IQR)	36.7 (36.4–37.8)	36.7 (36.0–37.7)	36.8 (36.5–37.8)	
Min–Max	35.1–39.3	35.1–39.3	35.5–39.3	
Respiratory rate (breaths per min.)				
Mean (\pm SD)	25.0 (\pm 6.8)	28.6 (\pm 8.2)	23.1 (\pm 5.1)	0.0006
Median (IQR)	24.0 (20.0–26.5)	26.5 (22.0–34.0)	22.0 (20.0–24.0)	
Min–Max	15–46	15–43	18–46	
Oxygen saturation (%)				
Mean (\pm SD)	83.1 (\pm 17.8)	71.9 (\pm 24.1)	88.9 (\pm 9.5)	0.0016
Median (IQR)	90 (80–95)	81.5 (50.0–91.0)	92 (84.0–95.0)	
Min–Max	20–99	20–98	60–99	

SD: Standard deviation, IQR: Interquartile range

DISCUSSION

The COVID-19 pandemic has highlighted the crucial importance of diagnostic and predictive tools to guide medical decisions. This study assessed the ability of chest CT to predict mortality in patients infected with COVID-19. Through an analysis of multicenter data, we examined chest CT findings associated with mortality. Our initial results indicate a significant correlation between certain chest CT findings and mortality in COVID-19 patients. In particular, the presence of consolidations and the degree of lung involvement emerged as predictive factors. The prognosis of COVID-19 pneumonia is variable, and the referral of patients being admitted to emergency departments is crucial.

Our study shows that the extent of parenchymal lesions on chest CT is the best prognostic factor among the factors studied. Lung involvement $>25\%$ increased the risk of mortality by 16.27 times compared with lung involvement $\leq 25\%$. These results are consistent with previous studies that have established a link between the degree of lung parenchymal involvement on chest CT and disease severity in patients with

COVID-19, qualifying it as a key prognostic factor.^[14-18] A French study by Malécot *et al.*^[9] in a cohort of 515 patients with COVID-19 found that those with lung parenchymal involvement $\geq 50\%$ on chest CT had a significantly higher risk of mortality. These findings highlight the importance of chest CT as an early predictor of clinical outcomes in patients with COVID-19. Therefore, imaging features and dynamic changes may provide the most objective evidence to assess disease severity and predict clinical outcomes.

The study showed that consolidations were chest CT findings statistically associated with COVID-19-related mortality. This finding is identical to that made by several authors who correlate it with pathological observations of severe inflammatory exudation in the intra-alveolar spaces and the formation of hyaline membranes in patients with COVID-19.^[18-21] According to Xu *et al.*,^[20] diffuse alveolar damage and progressive respiratory failure triggered by COVID-19 are the main causes of mortality in severe cases of COVID-19. Hu *et al.*^[18] suggested that the presence of consolidations on chest CT may predict poor prognosis in patients with COVID-19.

Table 2: Chest CT findings of 76 patients hospitalized for COVID-19 in relation to clinical course.

Variable	Total (n=76), n (%)	Non-survivors (n=26), n (%)	Survivors (n=50), n (%)	P-value
Lobes involved				
Right lower	70 (92.1)	26 (100.0)	44 (88.0)	0.0887
Right middle	64 (84.2)	26 (100.0)	38 (76.0)	0.0061
Right upper	67 (88.2)	26 (100.0)	41 (82.0)	0.0238
Left lower	74 (97.4)	26 (100.0)	48 (96.0)	0.5438
Left upper	64 (84.2)	25 (96.2)	39 (78.0)	0.0490
Number of lobes involved per patient				
<5	16 (21.1)	1 (3.9)	15 (30.0)	0.0076
5	60 (78.9)	25 (96.1)	35 (70.0)	
Chest CT images				
Ground glass opacities	75 (98.7)	25 (96.2)	50 (100.0)	0.3421
Consolidations	37 (48.7)	20 (76.9)	17 (34.0)	0.0009
Subpleural lines	25 (32.9)	2 (7.7)	23 (46.0)	0.0007
Crazy-paving	24 (31.6)	12 (46.2)	12 (24.0)	0.0487
Pleural effusion	7 (9.2)	5 (19.3)	2 (4.0)	0.0424
Bronchial wall thickening	2 (2.6)	1 (3.8)	1 (2.0)	1.0000
Bilateral lung involvement				
Yes	71 (93.4)	26 (100.0)	45 (90.0)	0.1587
No	5 (6.6)	0 (0.0)	5 (10.0)	
Lung involvement				
Minimal (<10%)	15 (19.7)	1 (3.8)	4 (8.0)	<0.0001
Moderate (10–25%)	20 (26.3)	1 (3.8)	19 (38.0)	
Widespread (26–50%)	14 (18.4)	3 (11.5)	11 (22.0)	
Severe/critical (>50%)	27 (35.5)	21 (80.8)	6 (12.0)	

CT: Computed tomography, COVID-19: Coronavirus disease 2019

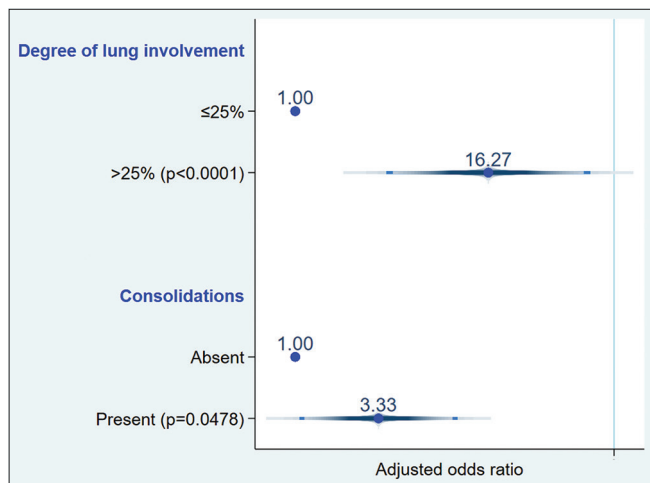


Figure 1: Multiple logistic regression of risk factors for mortality in adult inpatients with coronavirus disease 2019.

This study is one of the few to assess the prognostic value of CT images in predicting mortality in patients with COVID-19. Thanks to its multicenter approach, the study was able to enroll patients from three health facilities responsible for the management of COVID-19 infection in the province of North Kivu, making the results more or less generalizable. However, despite these strengths, the study is

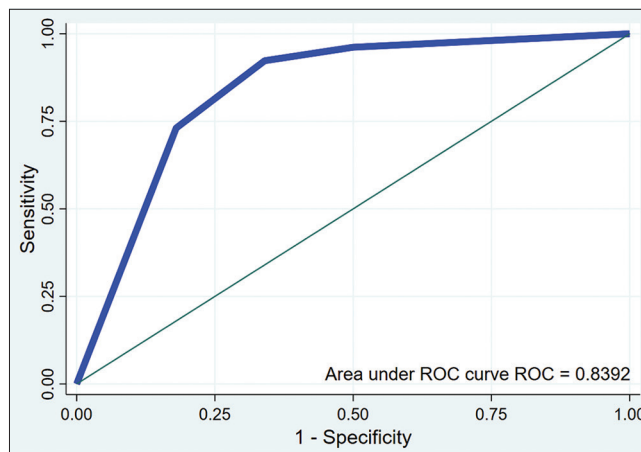


Figure 2: Receiver operating characteristic (ROC) curve evaluating the ability of thoracic computed tomography to predict mortality in adult inpatients with coronavirus disease 2019.

not without certain limitations, and the results shared must be interpreted with these limitations in mind. First, the study included a small number of patients and the chest CT scan studied was the first one performed during hospitalization. This implies a disparity in the duration of the disease course on the day of chest CT imaging. Second, the associations

presented in this study are not necessarily causal, as there may be residual or unmeasured confounding factors.

CONCLUSION

The results of this study make a significant contribution to the understanding of the factors predictive of mortality in adult inpatients with COVID-19 in Goma. An in-depth analysis of the degree of lung parenchymal involvement and the presence of consolidations on chest CT reveals a significant correlation with fatal disease outcomes. These findings underline the crucial importance of early and accurate CT assessment to better risk stratify patients, enabling targeted medical intervention and more effective management of severe cases of COVID-19. In addition, these results provide promising avenues for the development of personalized management protocols aimed at improving survival rates and optimizing medical resources in the specific context of Goma in the face of the COVID-19 pandemic.

Authors' contributions

All authors wrote and reviewed the manuscript.

Ethical approval

The research/study was approved by the Institutional Review Board at the Medical Ethics Committee of the University of Goma, number UNIGOM/CEM/009/2023, dated September 12, 2023.

Declaration of patient consent

Patient's consent not required as patients identity is not disclosed or compromised.

Financial support and sponsorship

Nil.

Conflicts of interest

There are no conflicts of interest.

Use of artificial intelligence (AI)-assisted technology for manuscript preparation

The author(s) confirms that there was no use of artificial intelligence (AI)-assisted technology for assisting in the writing or editing of the manuscript and no images were manipulated using AI.

REFERENCES

1. Fang Y, Zhang H, Xie J, Lin M, Ying L, Pang P, *et al.* Sensitivity of chest CT for COVID-19: Comparison to RT-PCR. *Radiology* 2020;296:E115-7.
2. Akl EA, Blažić I, Yaacoub S, Frija G, Chou R, Appiah JA, *et al.* Use of chest imaging in the diagnosis and management of COVID-19: A WHO rapid advice guide. *Radiology* 2021;298:E63-9.
3. Falaschi Z, Danna PS, Arioli R, Pasche A, Zagaria D, Percivale I, *et al.* Chest CT accuracy in diagnosing COVID-19 during the peak of the Italian epidemic: A retrospective correlation with RT-PCR testing and analysis of discordant cases. *Eur J Radiol* 2020;130:109192.
4. Caruso D, Zerunian M, Polici M, Pucciarelli F, Polidori T, Rucci C, *et al.* Chest CT features of COVID-19 in Rome, Italy. *Radiology* 2020;296:E79-85.
5. Lodé B, Jalaber C, Orcel T, Morcet-Delattre T, Crespín N, Voisin S, *et al.* Imaging of COVID-19 pneumonia. *J Imag Diagn Interv* 2020;3:249-58.
6. Herpe G, Lederlin M, Naudin M, Ohana M, Chaumoitre K, Gregory J, *et al.* Efficacy of chest CT for COVID-19 pneumonia in France. *Radiology* 2020;298:E81-7.
7. Metwally MI, Basha MA, Zaitoun MM, Abdalla HM, Nofal HA, Hendawy H, *et al.* Clinical and radiological imaging as prognostic predictors in COVID-19 patients. *Egypt J Radiol Nucl Med* 2021;52:100.
8. Colombi D, Villani GD, Maffi G, Risoli C, Bodini FC, Petrini M, *et al.* Qualitative and quantitative chest CT parameters as predictors of specific mortality in COVID-19 patients. *Emerg Radiol* 2020;27:701-10.
9. Malécot N, Chrusciel J, Sanchez S, Sellès P, Goetz C, Lévêque HP, *et al.* Chest CT characteristics are strongly predictive of mortality in patients with COVID-19 pneumonia: A multicentric cohort study. *Acad Radiol* 2022;29:851-60.
10. Li Y, Yang Z, Ai T, Wu S, Xia L. Association of "initial CT" findings with mortality in older patients with coronavirus disease 2019 (COVID-19). *Eur Radiol* 2020;30:6186-93.
11. Majrashi NA, Alhulaibi RA, Nammazi IH, Alqasi MH, Alyami AS, Ageeli WA, *et al.* A systematic review of the relationship between chest CT severity score and laboratory findings and clinical parameters in COVID-19 pneumonia. *Diagnostics* 2023;13:2223.
12. Société Française de Radiologie. SFR e-Bulletin. Paris: SFR. La société d'Imagerie Thoracique Propose un Compte-rendu Structuré de Scanner Thoracique Pour Les Patients Suspects de COVID-19 [The French Thoracic Imaging Society Proposes a Structured Chest Computerised Tomography Report for Patients with Suspected COVID-19]; 2020. Available from: <https://ebulletin.radiologie.fr/actualites-covid-19/societe-dimagerie-thoracique-propose-compte-rendu-structure-scanner-thoracique> [Last accessed on 2023 Sep 15].
13. Revel MP, Parkar AP, Prosch H, Silva M, Sverzellati N, Gleeson F, *et al.* COVID-19 patients and the radiology department - advice from the European Society of Radiology (ESR) and the European Society of Thoracic Imaging (ESTI). *Eur Radiol* 2020;30:4903-9.
14. Lanza E, Muglia R, Bolengo I, Santonocito OG, Lisi C, Angelotti G, *et al.* Quantitative chest CT analysis in COVID-19 to predict the need for oxygenation support and intubation. *Eur Radiol* 2020;30:6770-8.
15. Colombi D, Bodini FC, Petrini M, Maffi G, Morelli N,

- Milanese G, *et al.* Well-aerated lung on admitting chest CT to predict adverse outcome in COVID-19 pneumonia. *Radiology* 2020;296:E86-96.
16. Francone M, Iafrate F, Masci GM, Coco S, Cilia F, Manganaro L, *et al.* Chest CT score in COVID-19 patients: Correlation with disease severity and short-term prognosis. *Eur Radiol* 2020;30:6808-17.
 17. Pan F, Ye T, Sun P, Gui S, Liang B, Li L, *et al.* Time course of lung changes at chest CT during recovery from coronavirus disease 2019 (COVID-19). *Radiology* 2020;295:715-21.
 18. Hu Y, Zhan C, Chen C, Ai T, Xia L. Chest CT findings related to mortality of patients with COVID-19: A retrospective case-series study. *PLoS One* 2020;15:e0237302.
 19. Liu Q, Wang R, Qu G. Observation of corpse anatomy about coronavirus disease 2019 pneumonia decedent. *J Forensic Med* 2020;36:19-21.
 20. Xu Z, Shi L, Wang Y, Zhang J, Huang L, Zhang C, *et al.* Pathological findings of COVID-19 associated with acute respiratory distress syndrome. *Lancet Respir Med* 2020;8:420-2.
 21. Liu KC, Xu P, Lv WF, Qiu XH, Yao JL, Gu JF, *et al.* CT manifestations of coronavirus disease-2019: A retrospective analysis of 73 cases by disease severity. *Eur J Radiol* 2020;126:108941.

How to cite this article: Ndabahweje DN, Mukuku O, Kahindo CK, Tshikwela ML, Mvila GL, Aundu AM, *et al.* Prognostic value of chest computed tomography in adult inpatients with coronavirus disease 2019 pneumonia in Goma, in the Democratic Republic of the Congo. *J Pan Afr Thorac Soc.* doi: 10.25259/JPATS_31_2023